

Case Study: Comprehensive Treatment for Severe Rosacea using Intense Pulse Light and a Novel Non-Ablative 1064Nd:YAG

David M. Verebelyi, M.D.

Medical Director, Azure Medical, Denver, CO

Background

Historically, rosacea treatments consisted of prescribing oral antibiotics, steroids, and isotretinoin, focusing more on the immediate eruption of the disease rather than the lasting vascular and fibrotic sequelae. More recently, Intense Pulse Light (IPL) has been shown to aid in the resolution of the vascular telangiectasia and general erythema. To this point, no modality has effectively addressed the fibrotic consequences of this disease process. This case study addresses a rosacea treatment using antibiotics, Intense Pulse Light and a novel non-ablative 1064Nd:YAG (Yttrium, Aluminum, Garnet) laser which shows superior and longer lasting results than treatment from oral and IPL therapy alone.

Objective

To resolve current rosacea eruption, repair all depths of vascular damage, and improve the fibrotic sequelae of the disease using a combination of oral antibiotics and light therapy.

Method and Materials

A single patient with severe nodular rosacea was treated over a course of approximately 6 months. Standardized photographs were obtained preoperatively and during the course of the treatment. Patient results have continued to improve through the 6 month follow-up period.

Conclusion

Adding non-ablative, 1064Nd:YAG laser to IPL and antibiotics during the treatment of rosacea results in better overall cosmetic outcomes for the disease.

Introduction

There is no current consensus for the exact cause of rosacea. Although a significant increase in *Demodex folliculorum* has been found, the clinical significance of this is still in question. This hair mite may clog oil glands in susceptible patients, leading to the inflammation seen in rosacea. However, mite counts after one month of tetracycline antibiotics have shown no significant difference even though acute eruptions have resolved^{3,8}. *Helicobacter pylori* have also been studied as a possible cause. However, in a double blind controlled study on the effect of eradicating *H.pylori* found no benefit on the overall rosacea assessment score^{1,9}. Current research has focused more on a genetic level. Dr. Martin Steinhoff and

Dr. Thomas Luger, of the department of dermatology at the University of Muenster in Germany, examined how proteinase-activated receptor 2 (PAR-2) may affect endothelial cell function in rosacea skin. PAR-2 can serve as a receptor for several molecules, including dust mite antigens and bacterial proteases, which have a high impact on inflammatory response in the skin¹⁰. This combined with environment factors, such as mites or bacteria may account for some of the more puzzling characteristics of the disease. At its' core, rosacea is primarily a chronic vascular disorder that blooms in the presence of both the right genetic factor and environmental conditions. Treatment modalities that both alter the vascular pathogenesis and are able

to aid in the fibrotic sequelae, will be key instruments in developing satisfactory treatment regimens.

Rosacea treatment has classically consisted of topical and oral antibiotics with steroids and isotretinoin reserved for resistant cases. However, even with the most efficacious topical treatment, there is only a 35% patient satisfaction rate¹². In the last five years, several studies have been done utilizing IPL to deal with the diffuse erythema and telangiectatic matting that occur. In one study of 32 patients treated with IPL, 83% experienced reduced redness, 75% said they had less flushing and improved skin texture, and 64% reported fewer acne-like breakouts¹¹. Recurrence rates have been quoted at less than 1% over a three year follow-up⁷. But adding IPL is not effective treatment for the deeper vascular damage and fibrotic sequelae of the disease. Fibrosis and elastosis can be significant even in mild disease. This report consists of one case using antibiotics, Intense Pulse Light (IPL) and a novel non-ablative 1064Nd:YAG laser to achieve resolution of the acute eruption, telangiectasia, fibrosis and elastosis in a patient with severe rosacea. This achieved superior, long lasting results from what would be expected from antibiotic and IPL therapy alone.

Patients and Methods

A novel medical device, Laser Genesis, which consists of a non-ablative microsecond pulse for a 1064nm Nd:YAG and a 560nm IPL were used for treatment (Cutera, Brisbane, CA). This laser works in two ways. The first is selective thermolysis. Hemoglobin has a strong absorption peak just below 1000nm (Fig. 1). The 1064nm pulse created enough heat to provide selective thermolysis of vascular tissue in the papillary dermis, reaching vessels too deep to be addressed by the IPL. The second mechanism of action is through collagenesis. The microsecond pulse creates a temperature increase of 5°- 8°C in the papillary dermis. This is enough to stimulate cytokine release and bring fibroblast to the

site over the next seven to ten days¹³. Once there, these cells start depositing collagen into the treated area. Due to the overall increased temperature of the skin, mild flushing also occurs. This flushing gives the IPL a larger target and better absorption at lower fluences.

To perform the treatment, the area is thoroughly cleaned and photos are taken. A 5mm spot size is selected on the handpiece. Initial starting parameters are: fluence 13j/cm², 0.3 ms pulse duration, and 10 pulse/second frequency for Fitzpatrick skin types I-III. The handpiece is kept about 2cm over the skin and continuously moved back and forth in an airbrushing motion. This continuous movement protects any one area from thermal injury. Approximately 10,000-12,000 pulses are used. 4,000 pulses are done in each cheek with about 3,000 done over the forehead. IPL immediately follows the Laser Genesis procedure. Both procedures together take about 45 minutes to complete.

Our patient is a 40 year-old female patient, Fitzpatrick skin type II. She has a several year history of severe papulopustular rosacea. The patient was informed of the experimental nature of the treatment and was given an opportunity to ask any questions about the procedure. Appropriate operative consents were signed. A thorough history and physical were then performed including information on alcohol consumption and sun exposure. On exam, thick red plaques with pustules were noted over cheeks, forehead, upper lip and chin. Significant fibrotic scarring was noted on both cheeks from previous episodes (Fig. 2). The patient's face was thoroughly cleaned and pre-op photographs were taken using a Canon Digital Rebel XT with a Compact Macro lens EF 50mm 1:2.5 and Macro Ring Lite MR-14EX. Appropriate eye protection was put on by the patient and provider before the treatment began. Laser Genesis was performed over the entire face (Table 1) and then IPL was performed over the same area (Table 2). No anesthesia was necessary.

The patient rated the discomfort for the procedure a three out of a scale of ten. The patient started with Doxycycline 100mg po bid. After each of her treatments, a broad spectrum SPF 30 sunscreen with titanium dioxide was applied and appropriate after-care instructions were given. Patient had interim pictures taken 2 weeks after the second treatment (10 weeks into the process). The patient received a total of 5 treatments of Laser Genesis and 4 IPL treatments spaced approximately 4 weeks apart. Final pictures were taken approximately 4 weeks after last treatment.

Results

During a follow-up call 48 hours after the first procedure, the patient reported immediate subjective improvement in pustules and redness. At four weeks, there were no pustule on exam and the overall thickness of the plaques had improved. By the third treatment, most of the erythema over the forehead and chin had resolved (Fig. 3). Over the last two treatments, erythema continued to improve. The scarring over both cheeks improved by 30-50% after the fifth treatment (Fig. 4). Subjectively, the patient reported to be extremely happy with the results. Using a scale of one to ten (one being extremely unsatisfied and ten being ultimately satisfied) to measure the treatment and the results, this patient reported a ten.

Discussion

As collagen decreases with age and elastosis worsens due to continuing UV exposure, the supporting structure of cutaneous vessels breaks down. This may be one reason why rosacea tends to show up in the third decade and continues to worsen without treatment. Historically, antibiotics have been used with limited success, possibly functioning more

as anti-inflammatory agents. With the advent of IPL, outcomes have improved. The most popular IPL's tend to use short wavelengths, in the 500-600nm range. These shorter wavelengths do not penetrate well into the papillary dermis and therefore are not effective in dealing with deeper vascular tissue. Histology would likely be beneficial in understanding the depth of cellular change when using IPL vs. IPL plus the Nd:YAG. To this point, only a handful of scattered studies have begun to investigate this. Preliminary work suggests that the Nd:YAG works at least as far as the papillary or possibly into the deep dermis. It is also known that microsecond pulses from a 1064 Nd:YAG cause an immune mediated response that brings fibroblast into the area treated¹³. These lay down new collagen over the course of several days. This new collagen helps support existing vessels and fills in scarring from previous eruptions. The selective thermolysis from the 1064 Nd:YAG also aids in destroying deeper vessels. Adding IPL and Nd:YAG together may shorten overall treatment time but without a control group, this is difficult to ascertain.

Using an approach that views rosacea as primarily a vascular disorder that has pathology in different layers of the skin will improve outcomes. While IPL has advanced the level of patient satisfaction, there are still several aspects of the disease process that are not well treated. These include deeper vascular lesions, fibrosis and elastosis. This novel non-ablative Nd:YAG addresses these facets of the disease well and has an important place in the armamentarium of rosacea treatment both improving vascular clearance and decreasing the amount of scarring.

Table 1

Date	Fluence (j/cm ²)	Pulse duration (ms)	Frequency (Hertz)	Pulses
1/13/2006	13 j/cm ²	0.3ms	10	11,000
2/10/2006	14 j/cm ²	0.3ms	10	12,500
3/31/2006	15 j/cm ²	0.3ms	10	10,100
4/28/2006	15 j/cm ²	0.3ms	10	10,097
5/26/2006	15 j/cm ²	0.3ms	10	10,000

Table 2

Date	Fluence (j/cm ²)	Pulses
1/13/2006	19 j/cm ²	142
2/10/2006	19 j/cm ²	140
3/31/2006	20 j/cm ²	145
4/28/2006	*	*
5/26/2006	20 j/cm ²	143

* No IPL treatment done due to broken flash bulb

Fig. 1
Optical Absorption of Oxygenated and Deoxygenated Hemoglobin

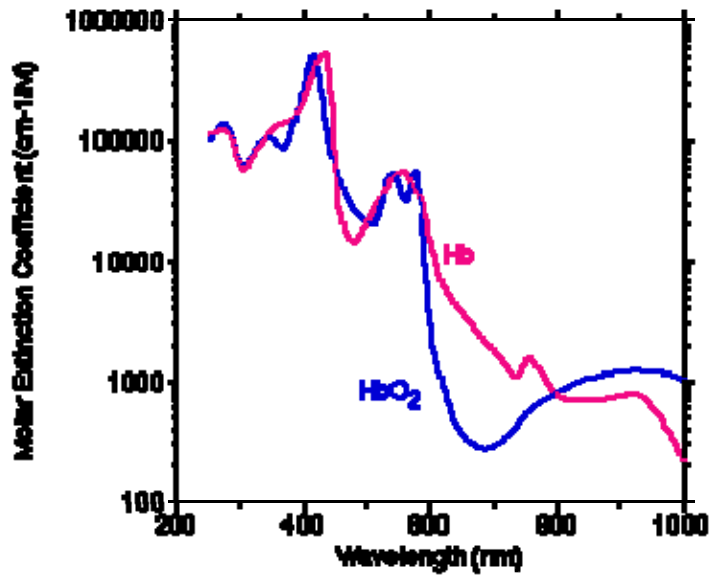


Fig.2

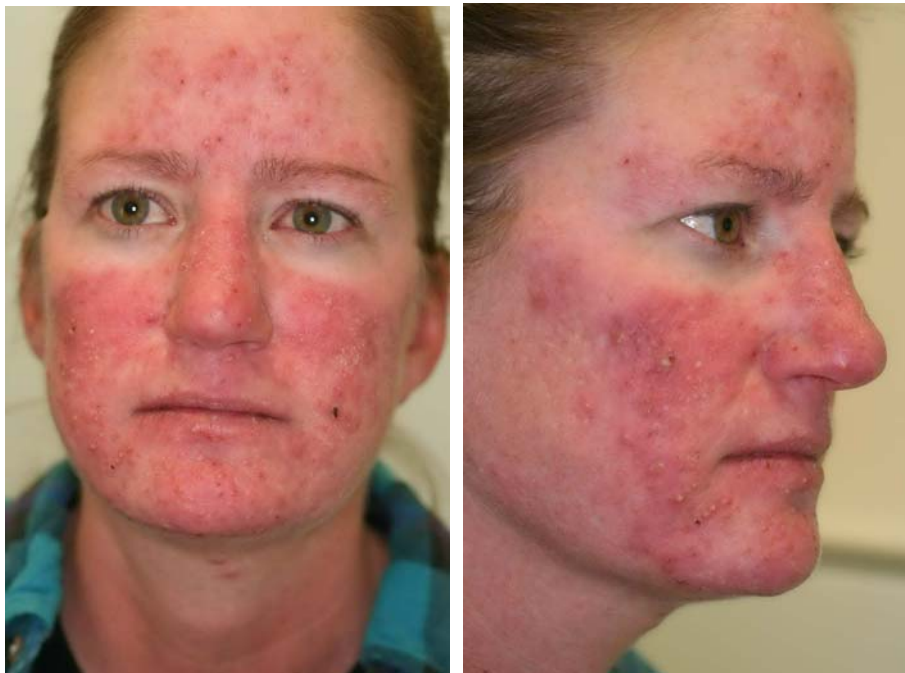

Fig. 3

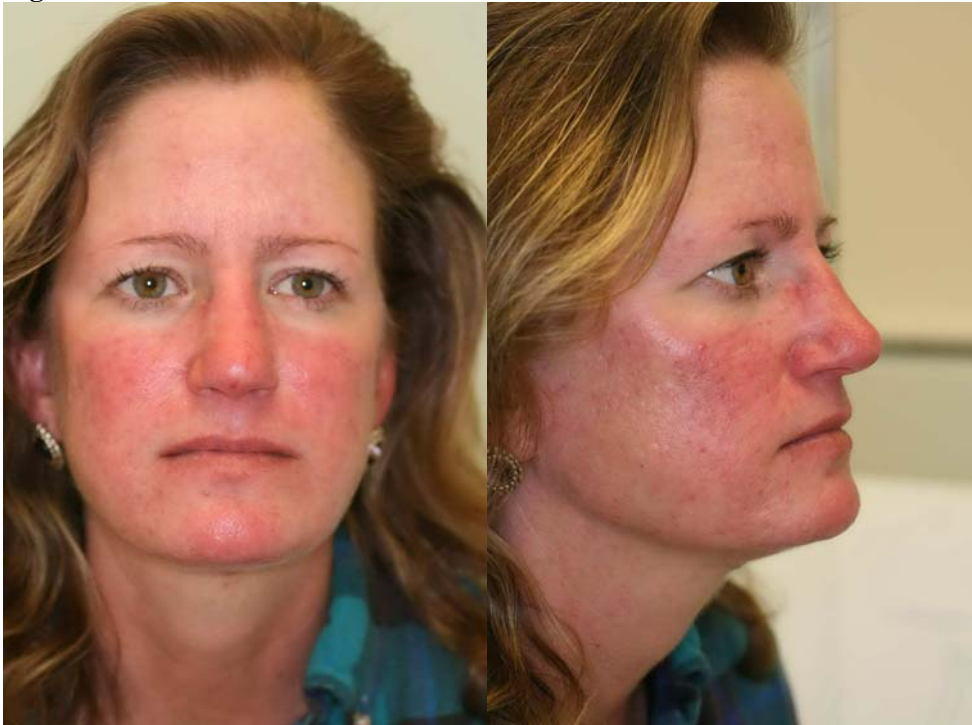
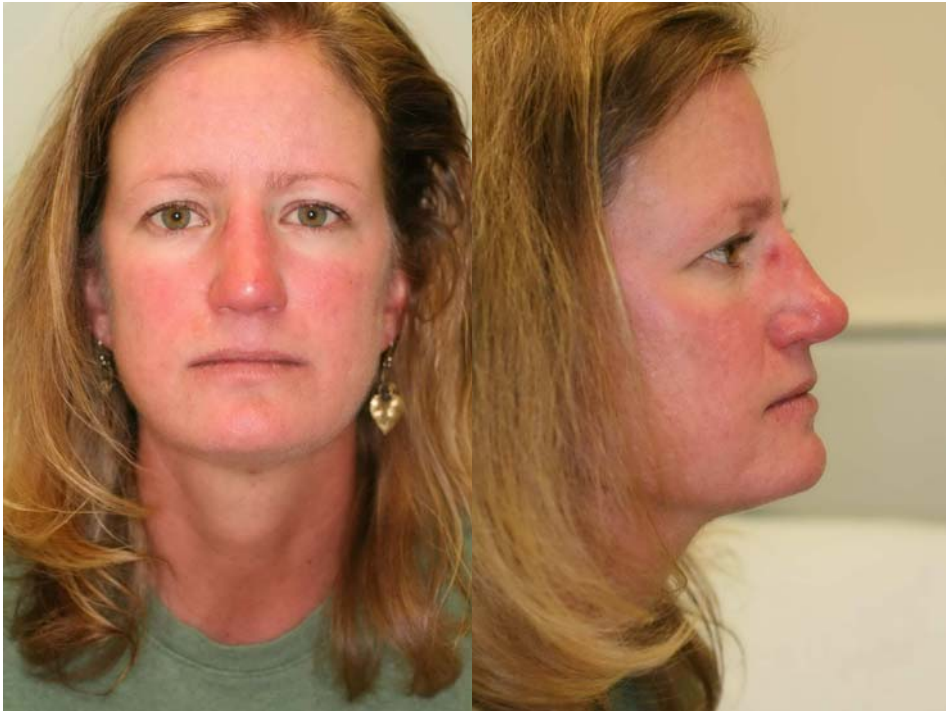
Fig. 4



References

1. Bamford JT, Tilden RL, Blankush JL, Gangeness DE. Effect of treatment of *Helicobacter pylori* infection on rosacea. *Arch Dermatol* 1999;35:659-63.
2. Ceilley RI. Advances in the topical treatment of acne and rosacea. *J Drugs Dermatol Sep* 2004;3(5Suppl):12-22.
3. Georgala S, Katoulis AC, Kylafis GD, Koumantaki-Mathioudaki E, Georgala S, Aroni K. Increased density of *Demodex folliculorum* and evidence of delayed hypersensitivity reaction in subjects with papulopustular rosacea. *J Eur Acad Dermatol Venereol* 2001;15:441-4.
4. Laube S, Lanigan SW. Laser treatment of rosacea. *Journal of Cosmetic Dermatology* Dec 2002;1(4):188-195.
5. Mark KA, Sparacio RM, Voigt A, Marenus K, Sarnoff DS. Objective and Quantitative Improvement of Rosacea-Associated Erythema After Intense Pulsed Light Treatment. *Dermatologic Surgery* Jun 2003;29(6):600-4.
6. Rone M, Kisis J. IPL therapy in the inflammatory stage of rosacea. *Journal of Cosmetic Dermatology* Jul 2002;1(2):105-110.
7. Schroeter CA, Haaf-von Below S, Neumann H. Effective Treatment of Rosacea Using Intense Pulsed Light Systems. *Dermatologic Surgery* Oct 2005; 31(10):1285-9.
8. Sibenge S, Gawkrödger DJ. Rosacea: a study of clinical patterns, blood flow, and the role of *Demodex folliculorum*. *J Am Acad Dermatol* 1992;26:590-3.
9. Son SW, Kim ICH, Oh CH, et al. The response of rosacea eradication of *Helicobacter pylori*. *Br J Dermatol* 1999;140:984-5.
10. Steinhoff M, Neisius U, Ikoma A, Fartasch M, Heyer G, Skov PS, Luger TA, Schmelz M. Proteinase-Activated Receptor-2 Mediates Itch: A Novel Pathway for Pruritus in Human Skin. *The Journal of Neuroscience* Jul 2003;23(15):6176-6180.
11. Taub, AF. Treatment of rosacea with intense pulsed light. *Journal of Drugs in Dermatology* Jun 2003;2(3):254-9.
12. Wolf, John E. Efficacy and Safety of Once-Daily Metronidazole 1% Gel Compared to Twice-Daily Azelaic Acid 15% Gel in the Treatment of Rosacea. 64th Annual Meeting of the American Academy of Dermatology Mar 2006; poster #562.
13. Yeh A. Imaging wound healing using optical coherence tomography and multiphoton microscopy in an in vitro skin-equivalent tissue model. *Journal of Biomedical Optics* April 2004;9(2):248-253